




Contents lists available at ScienceDirect

Journal of the World Federation of Orthodontists

journal homepage: www.jwfo.org

Case Report

A new, no-compliance class II correction strategy using nickel-titanium coil-springs

Luca Lombardo^{a,*}, Antonella Carlucci^b, Francesca Cervinara^c, Giuseppe Siciliani^d^a Adjunct Professor, Postgraduate School of Orthodontics, University of Ferrara, Ferrara, Italy^b Postgraduate Student, Postgraduate School of Orthodontics, University of Ferrara, Ferrara, Italy^c Private Practice in Bari, Italy^d Chairman of Postgraduate School of Orthodontics, Department of Orthodontics, University of Ferrara, Ferrara, Italy

ARTICLE INFO

Article history:

Received 15 October 2014

Received in revised form

27 November 2014

Accepted 3 December 2014

Available online 14 February 2015

Keywords:

Class II

Compliance-free

Spring

ABSTRACT

Background: Correcting Class II malocclusion with Class II elastics or functional appliances requires great patient collaboration. Here we describe two Class II cases successfully treated with an alternative approach using a fixed device designed to obviate compliance.

Methods: We fitted specific Class II springs to the bilateral hooks on the stainless steel maxillary and mandibular archwires of a full fixed appliance to correct the Class II malocclusion and to promote mandibular growth.

Results: The new device brought about full Class I canine and molar relationships in both treated cases and improved the maxillomandibular relationship without relying on patient collaboration.

Conclusion: Class II springs appear to be a simple, fast, and effective alternative approach to Class II correction, facilitating mandibular growth even in noncompliant patients.

© 2015 World Federation of Orthodontists.

1. Introduction

Various treatment strategies have been introduced for the correction of Class II malocclusion, and a range of different functional and interarch appliances, such as Class II elastics, have been proposed [1–3]. Class II elastics can be an effective means of correcting Class II malocclusions, exerting primarily dentoalveolar, rather than skeletal, effects [4].

However, Class II elastics, like many of these correction devices, are removable and therefore require great patient compliance, an influential factor that is difficult to predict before treatment is begun [5], but one that ideally needs to be taken into account before the treatment protocol is established [5].

Great interest has therefore been focused on techniques that minimize the need for patient cooperation, leading to the development of several devices, beginning with the first fixed functional appliance introduced by Herbst in 1905 [6].

The CS-2000 Class II correction device (DynaFlex, St. Ann, MO) has two closed coil-springs attached between the maxillary and mandibular archwires of a full fixed appliance. Although the device is fixed in the mouth, the springs act continuously, 24 hours a day,

unlike elastics, which act only when in position. By emulating the effects of devices such as Class II elastics, but without the need for patient compliance, the appliance was thus designed to permit faster resolution of the sagittal component of the malocclusion if used just after perfect alignment and leveling.

This article describes two cases of Class II patients—Class II Division 2 and Class II subdivision—successfully treated with the aid of the CS-2000 Class II springs.

2. Case 1

2.1. Diagnosis and etiology

The patient, a 12-year-old girl, was referred with a chief concern of dental crowding. No oral habits or temporomandibular joint symptoms were noted. Clinical examination showed a well-balanced and symmetrical face, with a good profile, competent lips, a good chin button, an obtuse nasolabial angle, and a retrognathic mandible.

The pretreatment intraoral photographs showed Class II molar and canine malocclusion on the right and the left sides, a good arch form, increased over jet and over bite, and a lower midline deviation of 1 mm to the right. The mandibular arch displayed minor crowding and deep curves of Spee and Wilson. Although her oral hygiene appeared poor, her periodontium was in good health.

* Corresponding author: Postgraduate School of Orthodontics, University of Ferrara, Via Montebello 31, Ferrara 44100, Italy.

E-mail address: lulombardo@tiscali.it (L. Lombardo).

The panoramic radiograph showed complete dentition, with the maxillary third molars present. The condyles appeared normal in size and form. Root length and bone height were normal, and no caries or other pathologies were noted (Fig. 1).

Under cephalometric analysis, the patient displayed skeletal Class II (point A, nasion, point B angle [ANB] 5°) with a horizontal growth pattern and a retruded mandible. The maxillary incisors were tipped lingually, but the mandibular incisors were ideally positioned (Table 1).

2.2. Treatment objectives

The treatment goals were to establish a Class I canine and molar relationship by aligning the maxillary and mandibular dental arches, to create ideal over jet and over bite, and to correct the lingual inclination of the maxillary incisors. A secondary objective was to stimulate mandibular growth and to improve the aesthetic profile of the patient. Hence a treatment plan was devised to align and level both arches to obtain perfect coordination, and then to

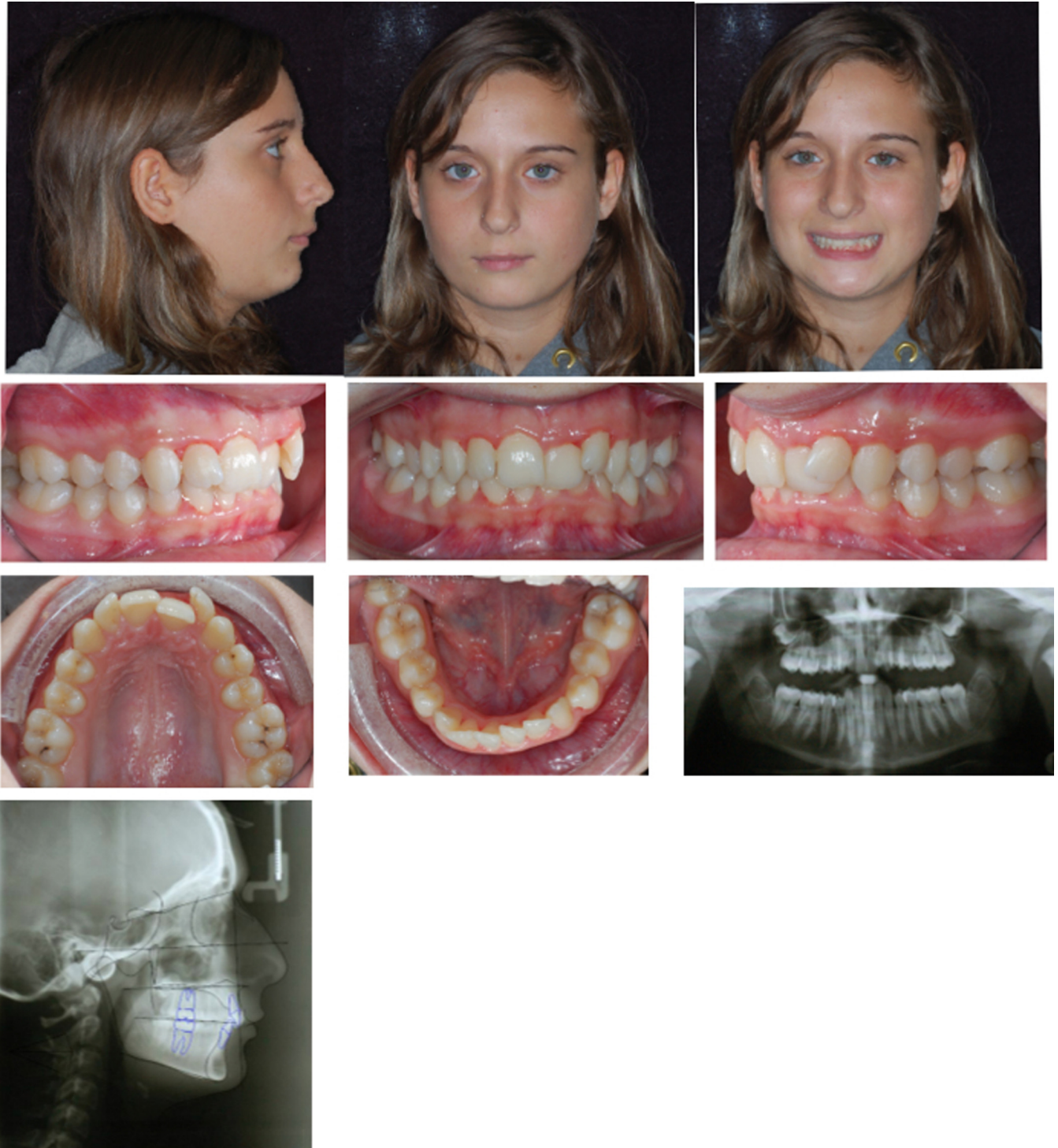


Fig. 1. Case 1: a 13-year-old female patient with skeletal and dental Class II relationship.

Table 1
Case 1: cephalometric data

	Normal	Pretreatment	Post-treatment
SNA (°)	82	76	76
SNB (°)	80	71	73
ANB (°)	2	5	3
A-Na Perp (mm)	0	-0.3	0.1
Pg-Na Perp (mm)	-4	-11	-6
FMA (°)	26	19	22
MP-SN (°)	33	32	33
PP-MP (°)	28	17	18
PP-OP (°)	10	4	8
MP-OP (°)	17	13	12
U1-Apo (mm)	6	3	3
L1-Apo (mm)	2	-2.8	1
U1-PP (°)	110	100	109
U1-OP (°)	54	75	60
L1-OP (°)	72	73	70
IMPA (°)	95	93	98
Over jet	2.5	5	3
Over bite	2.5	4	2

A-Na Perp, point A–nasion perpendicular distance; ANB, point A, nasion, point B angle; FMA, Frankfort mandibular plane angle; IMPA, incisor–mandibular plane angle; L1-Apo, lower central incisor to point A-pogonion line distance; L1-OP, lower central incisor–occipital plane angle; MP-OP, mandibular plane–occipital plane angle; MP-SN, mandibular plane–sella–nasion line angle; Pg-Na Perp, pogonion–nasion perpendicular distance; PP-MP, palatal plane–mandibular plane angle; PP-OP, palatal plane–occipital plane angle; SNA, sella, nasion, point A angle; SNB, sella, nasion, point B angle; U1-OP upper central incisor–occipital plane angle; U1-Apo, upper central incisor to point A–pogonion line distance; U1-PP, upper central incisor–palatal plane angle.

correct the Class II malocclusion with no-compliance closed coil-springs.

2.3. Treatment alternatives

The main issue for this patient was the correction of Class II malocclusion and aesthetic improvement of the profile. In growing patients just before the peak of pubertal growth, the objectives are to promote mandibular growth and favorable changes in dental and soft tissues while correcting the Class II relationship. There are several potential options for achieving these effects, broadly divided into: 1) a functional approach, using a removable appliance like the Twin Block or Fraenkel appliance, followed by a second phase using a full fixed appliance; and 2) an orthodontic approach, using Class II elastics or a fixed device like the Herbst appliance.

However, recent studies have demonstrated that orthodontic approaches are suitable for Class II correction but that their effects are mostly dentoalveolar rather than skeletal [4,7,8].

It is also possible to achieve the occlusal objectives by extracting either the upper first premolars and the lower second premolars or the upper first premolars alone. Nonetheless, in this case no extractions were proposed due to the potential for growth of the patient and the risk for worsening of the profile, with an increased obtuse nasolabial angle and a resulting biretrusive profile.

The possibility of a combined surgical/orthodontic treatment for mandibular advancement after the end of the growth spurt was discussed with the patient's parents. Because they refused the

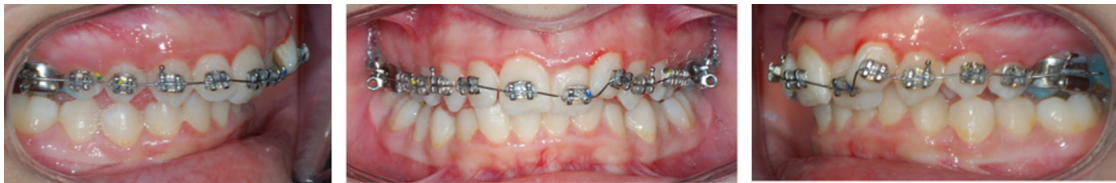

Fig. 2. Brackets bonded for alignment phase.

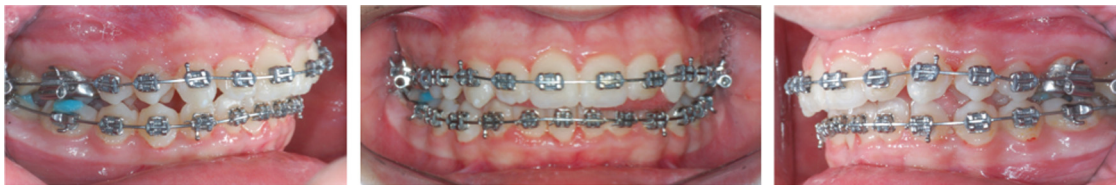

Fig. 3. Treatment progress: leveling phase with a 0.019 × 0.025-in copper-Ni-Ti.

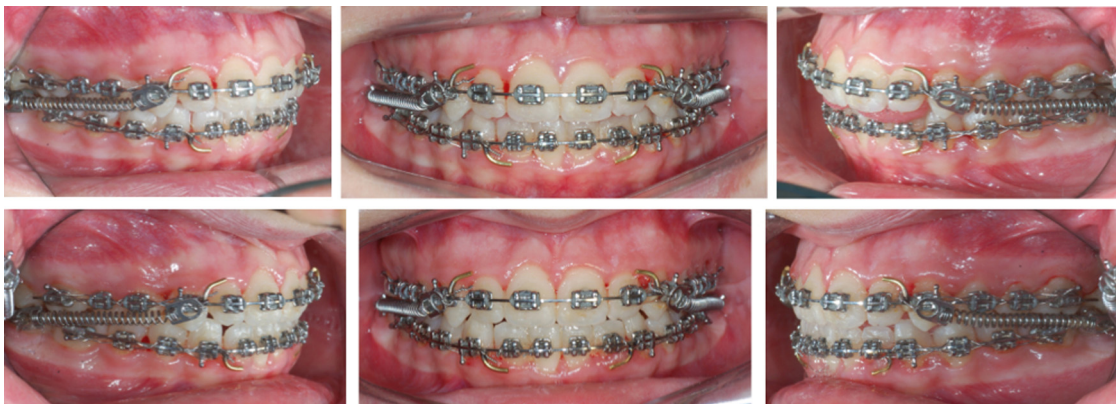

Fig. 4. CS-2000 Class II springs attached bilaterally from the maxillary hook of the 0.019 × 0.025-in stainless steel to the hook of the mandibular second molar tube.

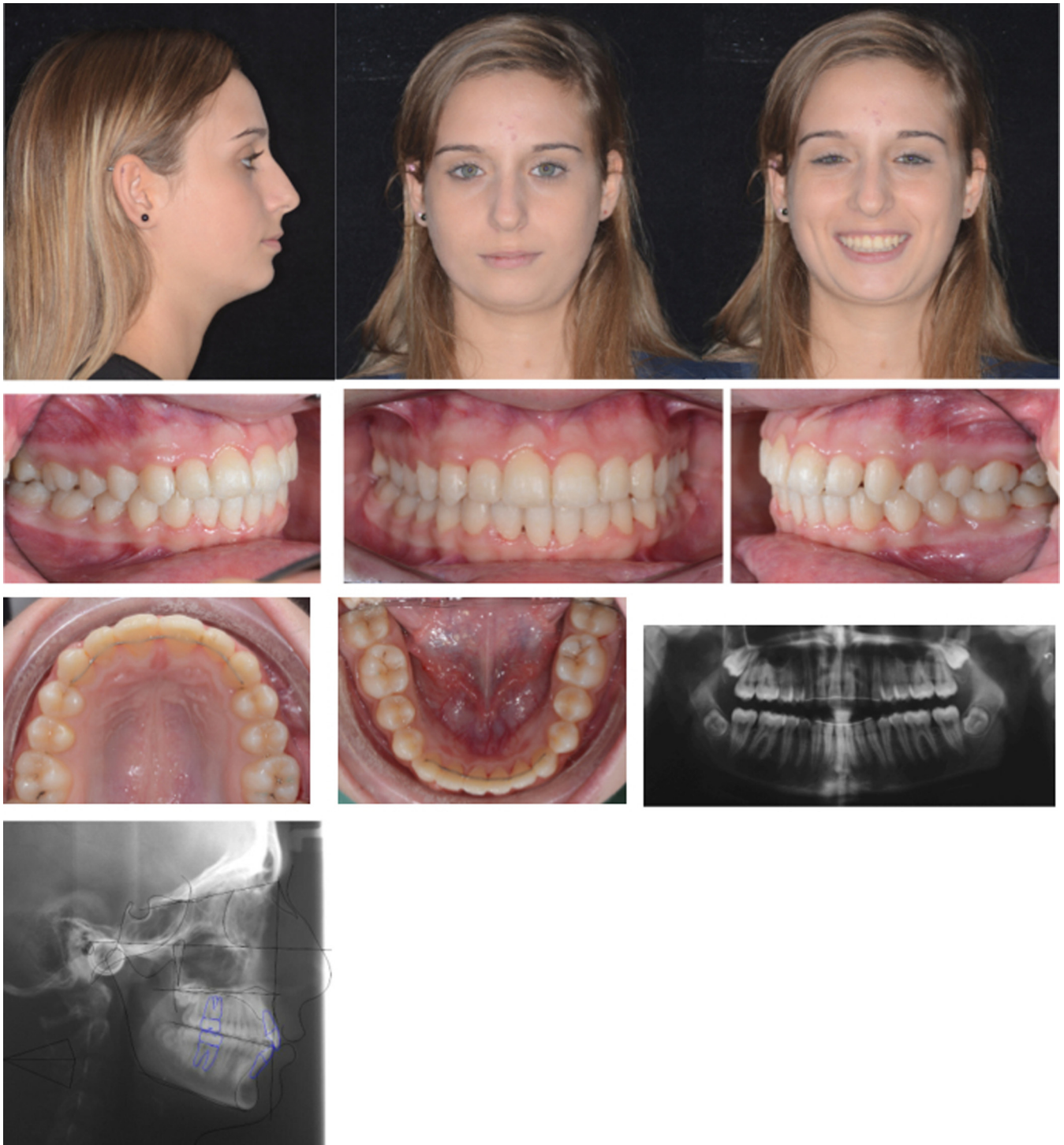

Fig. 5. Patient after 22 months of treatment.

surgical approach, an orthodontic nonextraction treatment with fixed appliances and a Class II no-compliance device was chosen.

2.4. Treatment progress

A straight-wire appliance with Straight Forward Philosophy prescription (Lancer Orthodontics, Vista, CA) was fitted to the maxillary arch, and a 0.016-in nickel-titanium (Ni-Ti) wire was inserted through the brackets to correct the crowding (Fig. 2). After

4 weeks, the mandibular arch was also bonded with the same appliance. Once the alignment had been achieved, the arches were levelled, progressing from 0.019 × 0.025-in thermal Ni-Ti to 0.019 × 0.025-in stainless steel archwires (Fig. 3). When alignment, levelling, and arch coordination had been accomplished, the CS-2000 Class II springs were attached to the device. The CS-2000 springs were originally designed to be fitted directly onto pivots threaded over a stainless steel archwire and secured with a screw. We elected instead to fix the springs bilaterally to the archwire

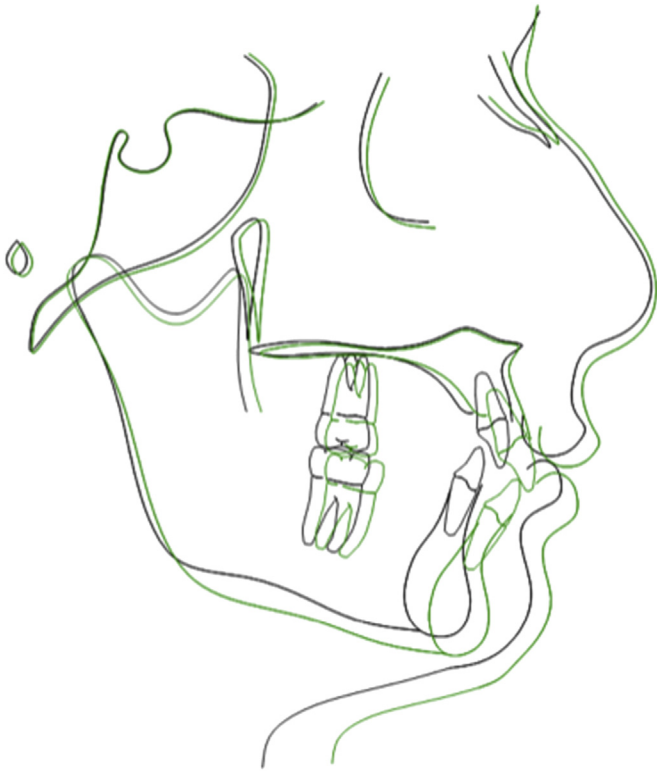


Fig. 6. Superimposition of pretreatment and post-treatment lateral cephalograms.

hooks using stainless steel ligatures. The upper end of each spring was thus fixed to the maxillary hook on the 0.019 × 0.025-in stainless steel archwire, and each lower end to the hook on the mandibular second molar tube. No adjustments or reactivations were needed after the springs had been fitted (Fig. 4).

The flexibility of the springs in question enables the jaws to be opened with relative ease, making the appliance suitable for use in adults as well as children. These springs provided the low, continuous force (about 200 g) necessary to correct the anteroposterior malocclusion. The anteroposterior force of the closed coil-springs enabled correction of the Class II malocclusion without relying on patient cooperation or repeated activations. Four months after the Class II springs were fitted, a Class I canine and molar relationship had been achieved. At this stage, the springs were easily detached before a 2-month detailing phase and ultimate removal of the fixed appliance. Fixed lingual retainers were then bonded to both arches, and the total treatment duration was 22 months.

2.5. Treatment results

Post-treatment records showed that all of the treatment objectives had been achieved, and the final results were considered satisfactory (Fig. 5). The cephalometric data showed that the maxillomandibular relationship had been corrected and that the mandibular position had improved, as evidenced by a 2° reduction in the ANB due to a significant increase in the anterior projection of point B (Table 1). A Class I molar and canine relationship had been achieved on both the right and the left, the over jet had been corrected, adequate over bite had been achieved, and the lower midline had been centered. The patient's aesthetic profile was much improved, and the increased lower incisor inclination was acceptable. The panoramic radiograph confirmed proper root parallelism, with no signs of root or bone resorption. For a detailed

comparison, the post-treatment lateral cephalogram was superimposed onto the pretreatment lateral cephalogram, and the effects of the class II springs were recorded. This analysis showed mesial movement of the mandibular first molars and moderate inclination of the maxillary and mandibular incisors (Fig. 6).

The 1-year follow-up photographs show a stable result, with a perfect molar and canine Class I relationship. The maxillary and mandibular incisors are in the proper positions, with adequate inclination, and the midlines remain centered (Fig. 7).

3. Case 2

3.1. Diagnosis and etiology

A 12-year-old female patient presented with a slight Class II subdivision left malocclusion, and minor crowding in both arches (Fig. 8). The pretreatment frontal facial photographs showed competent lips but some degree of skeletal mandibular asymmetry based on chin point deviation to the left. The lateral view showed a normal nasolabial angle and a retrognathic mandible. Incisor exposure during smile was good, but the smile was slightly gummy.

Clinical examination showed slight crowding in both arches, as well as increased over jet and over bite. The maxillary dental midline was coincident with the facial midline, but the mandibular dental midline was deviated 2.0 mm to the left of the facial midline. Although orthopantomography and lateral telerradiography had been performed 2 years previously, it was decided to not repeat these scans to avoid undue x-ray exposure.

Cephalometric analysis indicated a Class II skeletal relationship due to a retrognathic mandible. Posteroanterior telerradiography was deemed unnecessary due to the slight asymmetry. Despite this, the upper incisor inclination was within the normal range, but the lower incisors were significantly proclined (Table 2).

3.2. Treatment objectives

The main objective was to achieve a Class I canine and molar relationship, improving the projection of the mandible and the patient's facial aesthetics. A one-phase treatment plan was designed to correct the left unilateral Class II malocclusion, improve the over jet and over bite, correct the lower midline, and enhance the patient's aesthetic profile.

3.3. Treatment alternatives

The options of asymmetrical extraoral traction to distalize the left side of the upper arch and asymmetrical extraction from the upper arch were rejected in light of the symmetry of the upper maxilla and the mandibular retrusion. Asymmetrical mandibular advancement via orthodontic treatment with a full fixed appliance and asymmetric Class II elastics on the left side is a viable means of correcting Class II subdivision cases caused by mandibular skeletal asymmetry, but the patient refused to cooperate with the elastics. Hence, an orthodontic nonextraction treatment with fixed appliances and a Class II no-compliance coil-spring was proposed.

3.4. Treatment progress

Treatment with a full fixed straight-wire appliance (McLaughlin, Bennett, Trevisi prescription) was begun. The archwire sequence was identical to that in case 1, using a 0.016-in Ni-Ti for alignment, with progress from 0.019 × 0.025-in copper-Ni-Ti to 0.019 × 0.025-in stainless steel (Fig. 9).

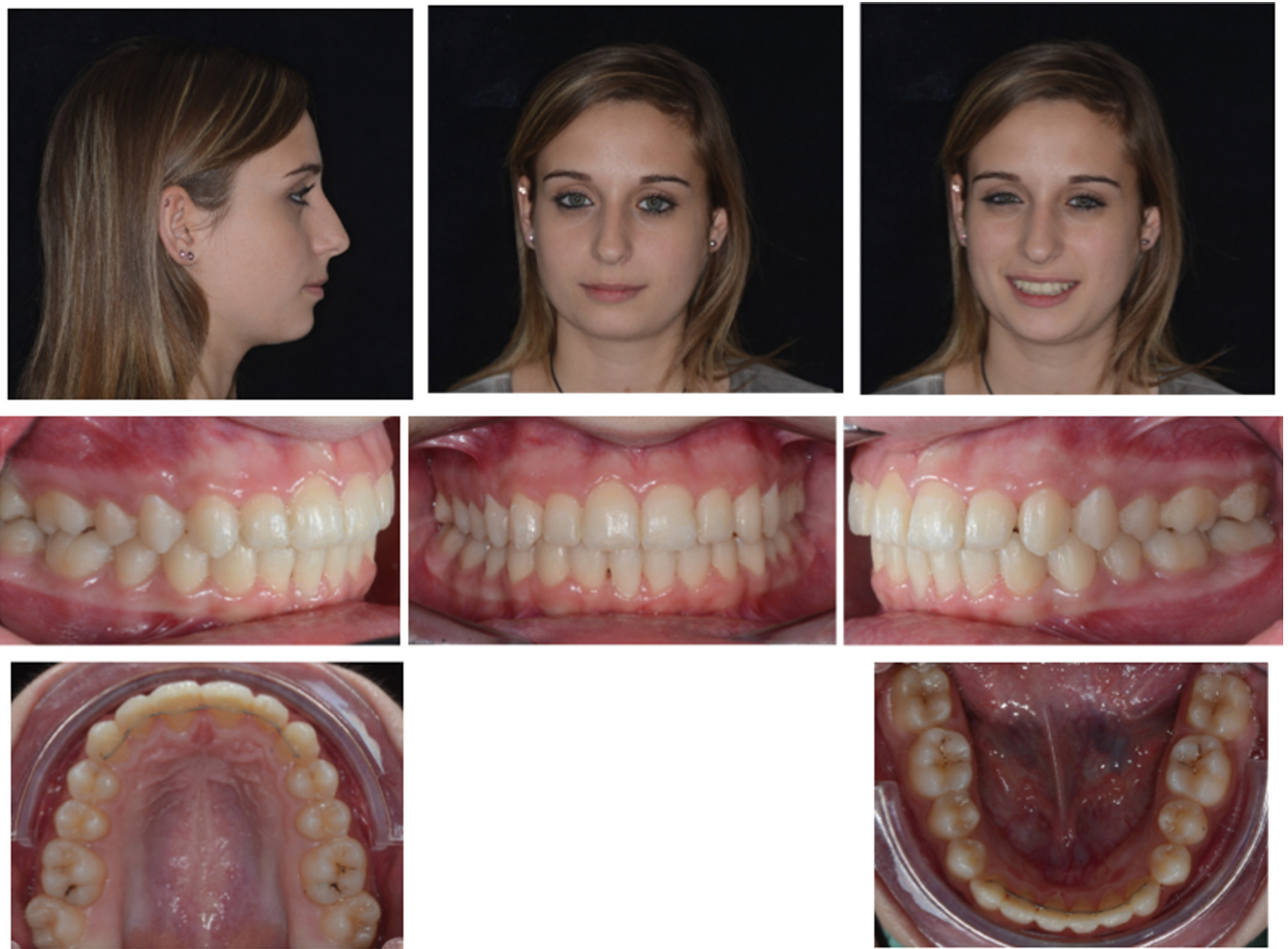

Fig. 7. One-year follow-up.

When alignment and leveling had been achieved, a single closed coil-spring was fixed on the left side from the maxillary hook of the 0.019×0.025 -in stainless steel to the hook on the mandibular second molar tube. Canine and molar Class I were achieved within 5 months of placement of the coil-spring, which was therefore removed, whereas the fixed appliances were left in place until stable intercuspitation had been established (a further 4 months). Lingual fixed retainers were bonded on both arches. The total treatment time was 21 months.

3.5. Treatment results

Post-treatment records showed Class I molar and canine relationships, along with normal over jet and over bite and centered midlines. The post-treatment cephalometric radiograph demonstrated a significant improvement in the sagittal jaw relationship due to mandibular advancement, with no change in the vertical jaw relationship (Fig. 10). The lower incisors were proclined (about 8°) as a result of the dentoalveolar compensation.

Superimposition of the pre- and post-treatment lateral cephalograms revealed a slight inclination of the maxillary and mandibular incisors within the alveolar bone. Nonetheless, the proclination of the mandibular incisors was deemed acceptable due to the morphology of the symphysis. The condylar region suggested some mandibular growth by the patient during the treatment (Fig. 11).

4. Discussion

The effects of this treatment protocol were satisfactory. The changes produced by the CS-2000 Class II springs seem to be similar to those produced by the other Class II no-compliance correction appliances like the Herbst appliance, the Jasper jumper, the adjustable bite corrector, and the Eureka Spring. In both cases, the cephalometric tracings indicated significant movement of the dentoalveolar complex and changes in the skeletal component of the malocclusion of a lesser magnitude (Tables 1 and 2). The ANB value was reduced in both cases, indicating some mandibular adjustment.

The short duration of the active treatment with the CS-2000 Class II springs, 4 and 5 months, respectively, in cases 1 and 2, may explain the smaller percentage of skeletal changes noted. Indeed, Janson et al. [4] also reported that the effects of Class II elastics are mainly dentoalveolar, including lingual tipping, retrusion and extrusion of the maxillary incisors, and labial tipping and intrusion of the mandibular incisors, in addition to mesialization and extrusion of the mandibular molars. Those authors also stated that, long-term, these effects are similar to those produced by functional appliances.

During active treatment with the CS-2000 Class II springs, we found in both cases (1 and 2) that the movements of the maxillary incisors and the mandibular molars were minimal. Once again, this finding may be correlated with the short duration of the treatment.

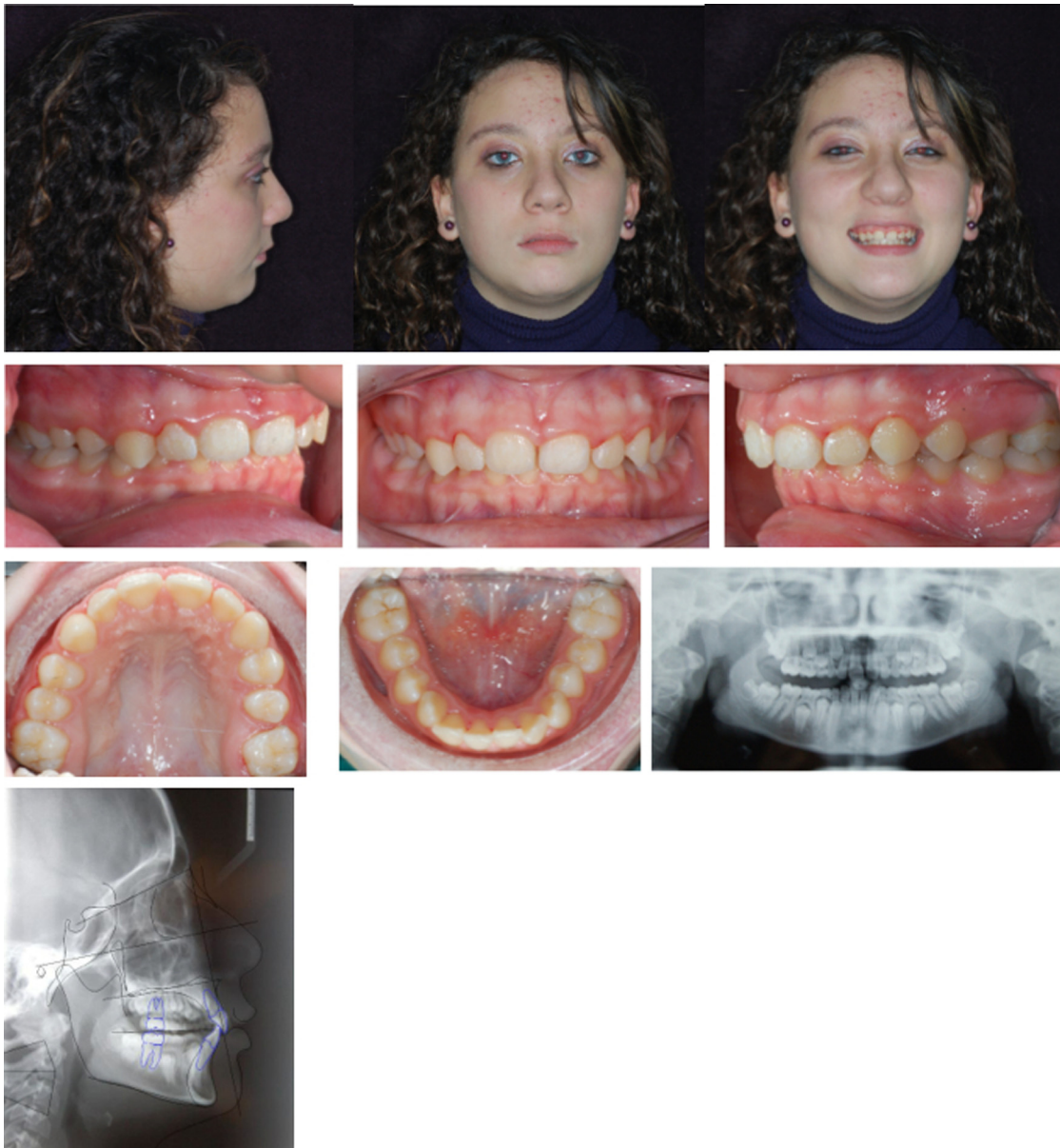

Fig. 8. Case 2: a 12-year-old female patient with skeletal Class II malocclusion, retrusive mandible, and compensatory lower incisor inclination.

Proclination of the mandibular incisors did occur (5° and 8° in cases 1 and 2, respectively), but this movement was similar in both magnitude and direction to that reported with Class II elastics and functional appliances [9–12].

No changes in vertical dimension were observed (Tables 1 and 2). The sella, nasion, mandibular plane angle remained stable in both cases. Similar effects have been shown with the Herbst [13] and Eureka Springs appliances [8], although not with other functional appliances or Class II elastics [14].

The palatal plane remained stable during the CS-2000 Class II coil-spring treatment. Such stability has been reported previously with the Herbst appliance and Jasper jumper regimens. In contrast, functional appliances, Class II elastics, and cervical traction headgear all tip the maxilla downward and backward, thereby increasing the anterior facial height [15,16].

With regard to the interdental changes, active treatment with CS-2000 Class II coil-springs reduced both the over jet and the over bite and improved the molar relationship in both cases.

In particular, in case 1, the correction of the molar relationship was associated with a slight mesialization of the mandibular molars, whereas in case 2 the reduction in overbite was attributable to significant intrusion of the mandibular incisors. A recent systematic review reported mean reductions of 5.8 mm in over jet correction and 3 mm in over bite correction with Class II elastics. A study by Nelson [17] reported that the over jet and over bite corrections achieved with Class II elastics were more significant with respect to those achieved with the Herbst appliance. However, with the latter, the correction was due more to skeletal changes than to dentoalveolar movements as in this case [4].

5. Conclusions

Although Class II elastics are commonly used for Class II correction, the need for patient compliance is a significant

Table 2

Case 2: cephalometric data

Measurements	Normal	Pretreatment	Post-treatment
SNA (°)	82	75	76
SNB (°)	80	70	73
ANB (°)	2	5	3
A-Na Perp (mm)	0	0.4	-1
Pg-Na Perp (mm)	-4	-8.7	-7
FMA (°)	26	26	29
MP-SN (°)	33	40	40
PP-MP (°)	28	24	23
PP-OP (°)	10	8	8
MP-OP (°)	17	16	15
U1-Apo (mm)	6	4.1	4.8
L1-Apo (mm)	2	1.3	2
U1-PP (°)	110	105	113
U1-OP (°)	54	66	59
L1-OP (°)	72	63	56
IMPA (°)	95	101	109
OVJ	2.5	3	2.5
OVb	2.5	2.2	1

A-Na Perp, point A–nasion perpendicular distance; ANB, point A, nasion, point B angle; FMA, Frankfort mandibular plane angle; IMPA, incisor–mandibular plane angle; L1-Apo, lower central incisor to point A-pogonion line distance; L1-OP, lower central incisor–occipital plane angle; MP-OP, mandibular plane–occipital plane angle; MP-SN, mandibular plane–sella-nasion line angle; Pg-Na Perp, pogonion-nasion perpendicular distance; PP-MP, palatal plane–mandibular plane angle; PP-OP, palatal plane–occipital plane angle; SNA, sella, nasion, point A angle; SNB, sella, nasion, point B angle; U1-OP upper central incisor–occipital plane angle; U1-Apo, upper central incisor to point A–pogonion line distance; U1-PP, upper central incisor–palatal plane angle.

limiting factor, affecting both the duration of treatment and the quality of the result achieved. Hence, eliminating the need for patient cooperation and delivering continuous forces give fixed functional appliances a distinct advantage over removable appliances. The cases presented here show that CS-2000 Class II springs represent a simple, more rapid and safe alternative to other Class II corrective devices in patients who appear to be noncompliant.

Acknowledgment

Source of financial support: The authors have no financial relationships to disclose.

References

- [1] Graber TM, Rakosi T, Petrovic A. Dentofacial orthopedics with functional appliances. St. Louis: C.V. Mosby Co; 1997. p. 346–52.
- [2] McNamara Jr JA. Components of Class II malocclusion in children 8–10 years of age. *Angle Orthod* 1981;51:177–202.
- [3] Ritto AK. Fixed functional appliances—a classification. *Funct Orthod* 2000;17:12–30. 32.
- [4] Janson G, Sathler R, Fernandes TM, Branco NC, de Freitas MR. Correction of Class II malocclusion with Class II elastics: a systematic review. *Am J Orthod Dentofacial Orthop* 2013;143:383–92.
- [5] Shin-Jae L, Sug-Joon A, Tae-Woo K. Patient compliance and locus of control in orthodontic treatment: a prospective study. *Am J Orthod Dentofacial Orthop* 2008;133:354–8.
- [6] Pancherz H. The Herbst appliance: its biologic effects and clinical use. *Am J Orthod* 1985;87:1–20.
- [7] Edwards JG. Orthopedic effects with “conventional” fixed orthodontic appliances: a preliminary report. *Am J Orthod* 1983;84:275–91.
- [8] Stromeyer EL. A cephalometric study of the Class II correction effects of the Eureka spring. *Angle Orthod* 2002;72:203–10.
- [9] Pancherz H. Treatment of Class II malocclusions by jumping the bite with the Herbst appliance. *Am J Orthod* 1979;76:423–44.
- [10] Pancherz H. The mechanism of Class II correction in Herbst appliance treatment. A cephalometric investigation. *Am J Orthod* 1982;82:104–13.
- [11] Gianelly AA, Arena S, Berstein L. A composition of Class II treatment changes noted with the light wire, edgewise, and Frankel appliances. *Am J Orthod* 1984;86:269–76.
- [12] Pancherz H, Hansen K. Mandibular anchorage in Herbst treatment. *Eur J Orthod* 1974;65:531–8.
- [13] Sabine R, Pancherz H. The effect of Herbst appliance treatment on the mandibular plane angle: a cephalometric roentgenographic study. *Am J Orthod Dentofac Orthop* 1996;86:269–76.
- [14] Luder HU. Skeletal profile changes related to two patterns of activator effects. *Am J Orthod* 1982;91:143–51.
- [15] Herzberg R. A cephalometric study of Class II relapse. *Angle Orthod* 1973;43:112–8.
- [16] Proffit WR. Contemporary orthodontics. St. Louis: C.V. Mosby Co.; 1986. p. 503–4. p.
- [17] Nelson B, Hägg U, Hansen K, Bendeus M. A long-term follow-up study of Class II malocclusion correction after treatment with Class II elastics or fixed functional appliances. *Am J Orthod Dentofacial Orthop* 2007;132:499–503.

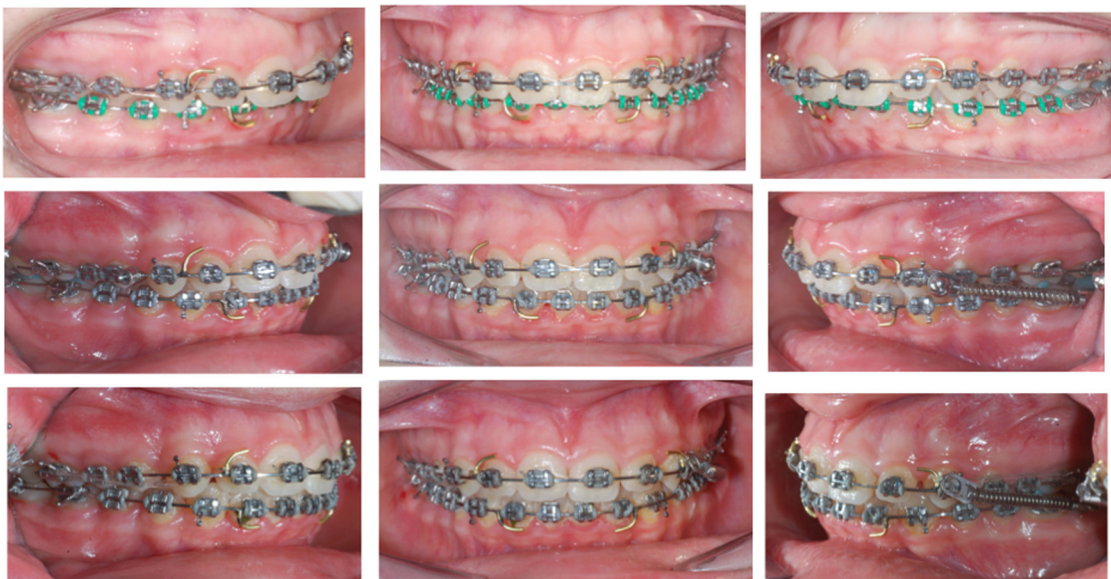

Fig. 9. Treatment progress.

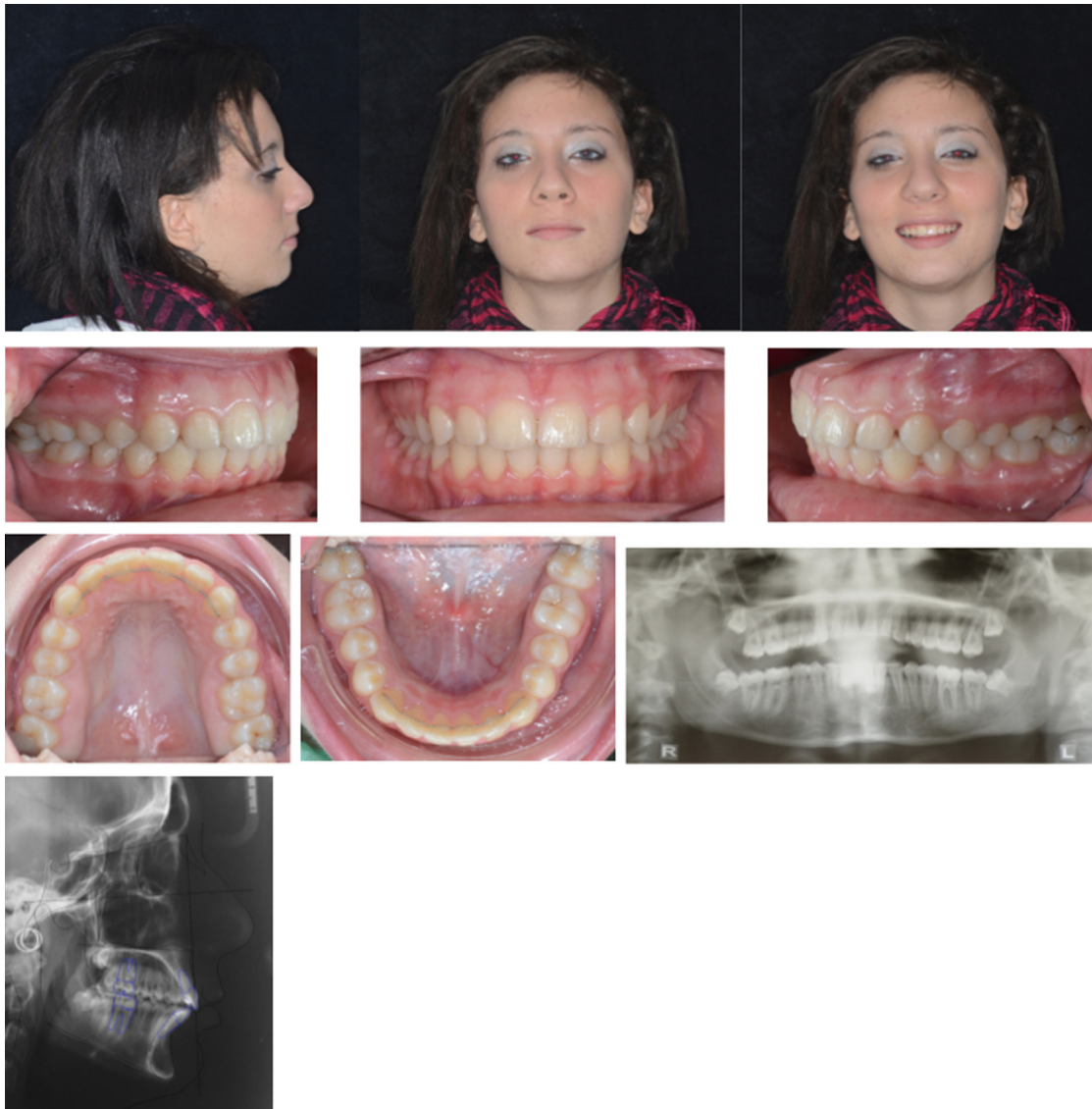

Fig. 10. At the end of treatment, after 21 months.

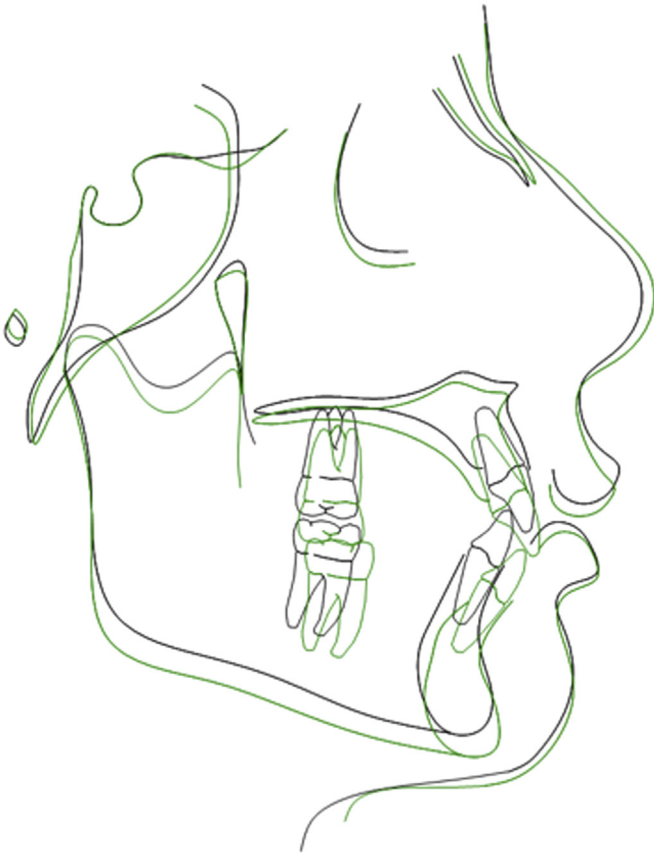

Fig. 11. Superimposition of lateral ceph tracings.