

Effect of RME and headgear treatment on the eruption of palatally displaced canines

A randomized clinical study

Pamela Armi^a; Paola Cozza^b; Tiziano Baccetti^c

ABSTRACT

Objective: To determine the effectiveness of orthodontic treatment finalized on the maintenance/improvement the upper arch perimeter to assist in the successful eruption of palatally displaced maxillary canines (PDCs).

Materials and Methods: The randomized prospective design comprised 64 subjects with PDCs who were randomly assigned to one of three groups: cervical pull headgear (HG); rapid maxillary expansion and cervical pull headgear (RME/HG); or untreated control group (CG). Panoramic radiographs and lateral cephalograms were evaluated at the time of initial observation (T1) and after an average period of 18 months (T2). At T2 the success of canine eruption was evaluated. A superimposition study on lateral cephalograms was undertaken to evaluate the T1–T2 changes in the sagittal position of the upper molars in the three groups.

Results: The prevalence of successful eruption was 85.7% in the RME/HG group and 82.3% in the HG group. Both these prevalence rates were significantly greater than the success rate in untreated control subjects (36%). The cephalometric superimposition study showed a significant mesial movement of the upper first molars in the CG compared with the HG and RME/HG groups.

Conclusions: The use of rapid maxillary expansion and headgear (or headgear alone) in PDC cases increases the success rate of eruption of the canine significantly (almost three times more than in untreated controls). (*Angle Orthod.* 2011;81:370–374.)

KEY WORDS: Palatally displaced canines; Rapid maxillary expansion; Headgear; Interceptive treatment

INTRODUCTION

Palatal displacement of the maxillary canine is defined as the “developmental dislocation of the upper canine [...] to a palatal site often resulting in tooth impaction requiring surgical and orthodontic treat-

ments.”¹ The prevalence of palatally displaced canines (PDCs) fluctuates between 0.8% and 5.2%.^{2–6} The most frequent consequence of PDCs is impaction of the canine.^{7–9} If orthodontic treatment (early or interceptive treatment) is not started in a timely manner in subjects with a PDC, other possible sequelae may occur, such as resorption of the roots of the neighboring permanent teeth^{10–12} and cysts.^{4,13,14} Several treatment procedures (or associations of them) have been proposed for impacted canines, and they are complex, require interdisciplinary work, and are expensive for the patient: surgical exposure of the crown of the canine, either performed alone or followed by orthodontic traction of the impacted tooth^{14–16} extraction of the canine and replacement with implants¹⁷; and reimplantation of the displaced tooth.^{18,19}

Despite extensive interest in both etiology and therapy of PDC, only a few studies in the past 20 years have focused on preventive measures for canine palatal impaction.^{7,20–24} The clinical protocols proposed include extraction of the corresponding primary canine,

^a Research Assistant, Department of Orthodontics, The University of Florence, Florence, Italy.

^b Professor and Department Chair, Department of Orthodontics, Università degli Studi di Roma “Tor Vergata,” Rome, Italy.

^c Associate Professor, Department of Orthodontics, The University of Florence, Florence, Italy; Thomas M. Graber Visiting Scholar, Department of Orthodontics and Pediatric Dentistry, School of Dentistry, The University of Michigan, Ann Arbor, Mich.

Corresponding author: Dr Tiziano Baccetti, Department of Orthodontics, Università degli Studi di Firenze, Via Ponte di Mezzo 48 Firenze, Italy 50127 Italy (e-mail: tbaccetti@unifi.it)

Accepted: November 2010. Submitted: June 2010.

Published Online: February 7, 2011

© 2011 by The EH Angle Education and Research Foundation, Inc.

with or without orthodontic procedures to gain space in the upper arch (ie, distalization of the upper buccal segments, maxillary expansion).^{23,24} The procedure of reducing the prevalence of impacted PDC by extracting the primary canine has been reported in the dental literature since Buchner.²⁵ The outcomes in several individual subjects during the subsequent 50 years corroborated the clinical recommendation for this interceptive measure.²¹ Finally, the prospective study by Ericson and Kuroi²⁰ analyzed the effects of extraction of the primary canine on PDC in terms of rate and time of "spontaneous" eruption. In 36 of 46 canines (78%), palatal eruption changed to normal, with the eruption time ranging from 6 to 12 months. In a longitudinal 2-year investigation, Power and Short²² described the achievement of a normal eruptive position of PDC in 62% of the subjects after extraction of the primary canines. Those authors suggested combining the tooth extraction with procedures to increase arch length, such as distalization of the upper buccal segments.

A randomized controlled trial by Baccetti and colleagues,⁸ which incorporated untreated controls and a statistically appropriate number of subjects, showed that extracting the primary canine is an effective procedure to increase the rate of normal eruption of maxillary PDC (two times more than in untreated controls). Use of a cervical pull headgear in addition to extracting the primary canine significantly increased the rate of successful eruption of the permanent canine (almost three times more than in untreated controls). In a recent study,⁹ the use of rapid maxillary expansion (RME) in the very early developmental phases (at the age of 8 or 9 years) in subjects where PDC had been diagnosed on posteroanterior (PA) films according to Sambataro and colleagues²⁶ showed a success rate of about 65%.

The aims of the present randomized clinical trial, which included an untreated control group, were as follows:

- To evaluate the prevalence of successful eruption of PDC during orthodontic treatment finalized to maintenance/improvement of the upper arch perimeter (headgear or RME in combination with headgear) in absence of the extraction of the deciduous canine corresponding to the PDC;
- To assess the changes in the sagittal position of the upper teeth posterior to the deciduous canine (upper first molars) after the interceptive treatment approaches.

MATERIALS AND METHODS

The examined sample consisted of subjects enrolled in a prospective study at the Department of Orthodontics of the University of Florence and at the Department of Orthodontics of the University of Roma (Tor Vergata). The study project was approved by the

Ethical Committee at the University of Florence and Rome. The following inclusion criteria had to be fulfilled by the subjects enrolled in the study:

- White ancestry;
- Either unilateral or bilateral PDC on a panoramic radiograph. PDC was diagnosed as intraosseous palatal position of the maxillary permanent canines from panoramic radiographs and periapical radiographs. The displacement of the upper canine to the palatal side was checked by means of double-determination periapical radiographs;
- Dental age older than 8 years and younger than 13 years according to the method of Becker and Chaushu²⁷;
- Skeletal age showing active phases of skeletal growth according to the cervical vertebral maturation method (before CS 4)²⁸;
- Presence of mild crowding at the maxillary arch and/or molar relation showing Class II tendency.

The following exclusion criteria were established:

- Previous orthodontic treatment;
- Craniofacial syndromes, odontomas, cysts, cleft lip and/or palate, sequelae of traumatic injuries to the face, or multiple and/or advanced caries;
- Aplasia or severe hypoplasia of the crown of upper lateral incisors.

A sample of 64 subjects with 81 palatally displaced canines was enrolled for the study, and informed consent was obtained. The following material was collected in the PDC sample: panoramic radiographs and lateral cephalograms at time of initial observation (T1) and after an average period of 18 months subsequent to T1 (T2); and dental casts at T1. For each patient the radiographs at T1 and at T2 were taken with the same radiograph machine. All subjects with PDCs were assigned randomly to one of the following three groups:

- Headgear (HG) group, where the cervical pull headgear was used alone for 1 year for 12–14 hours a day.
- Rapid maxillary expansion/headgear (RME/HG) group; these subjects were treated with a banded rapid maxillary expander (7 mm of active expansion; at the end of expansion all patients retained the expander for 6 month) followed by use of a cervical-pull headgear like in the HG group.
- Control group (CG); these subjects did not receive any treatment between T1 and T2.

Four subjects did not complete the clinical trial because they moved from the area of clinical care or asked to be transferred to other clinicians. The remaining 60 subjects showed the following distribution:

- HG group: 17 subjects, mean age of 11.9 years at T1, 9 males and 8 females, and 25 PDCs
- RME/HG group: 21 subjects, mean age of 11.1 years at T1, 9 males and 12 females, and 30 PDCs
- CG, 22 subjects, mean age of 11.6 years at T1, 9 males and 13 females, and 26 PDCs

Severity of canine displacement was similar in the three groups at T1, and it was not a discriminant factor for case assignment. The power of the present study was greater than 0.85.

Assessment of Successful Outcome

A successful outcome for PDC was defined as the full eruption of the tooth, thus permitting bracket positioning for final arch alignment when needed. Unsuccessful outcome was defined as the lack of eruption of the permanent canine at the completion of the clinical observation period (T2, 18 months after the initial observation).

Superimposition Study on Lateral Cephalograms

Change in the sagittal position of the upper first molar with regard to maxillary stable structures was performed according to the method of Björk and Skieller²⁹ by means of superimposition of the T2 film on the T1 film for each subject. The distance between the most mesial point on the crown of the molar at T1 and T2 was recorded by means of computerized cephalometric software (Viewbox, version 3.0, dHAL Software, Kifissia, Greece). A positive value would indicate mesial movement of the molar, a negative value distal movement of the molar.

Statistical Analysis

The prevalence rates of successful and unsuccessful subjects in the HG group were compared with those in the RME/HG group and the CG by means of χ^2 tests with Bonferroni correction for multiple comparisons ($P < .016$). Kruskal-Wallis test with Bonferroni correction for multiple comparisons ($P < .016$) was used to evaluate the differences among the three groups with regard to the amount of molar movement as assessed in the cephalometric superimposition study.

All statistical computations were carried out with the aid of a commercial statistical package (Statistical Package for Social Sciences, release 10.0, SPSS Inc, Chicago, Ill).

RESULTS

Effectiveness of the Two interceptive Procedures

The prevalence rates of subjects with successful eruption of the permanent canine were 82.3% in the

HG group ($\chi^2 = 49.1$, $P < .001$) and 85.7% in the RME/HG ($\chi^2 = 55.2$, $P < .001$), which were significantly greater than those of the CG. No statistically significant difference was found for the prevalence of successful subjects between the HG and RME/HG groups ($\chi^2 = 0.07$, $P = .786$).

Change in the Sagittal Position of the Upper First Molars

The amount of mesial movement of the upper first molars was significantly smaller in the HG and RME/HG groups compared with the CG ($P < .01$). The average amount of sagittal displacement of the upper first molar in the two treatment groups (HG and RME/HG) was close to zero (0.2 mm in both groups), whereas it was 2.32 mm in the CG. It should be noted that none of the examined subjects presented with exfoliation of upper second primary molars at T2.

DISCUSSION

The present investigation reached an adequate power (> 0.85) because of the number of subjects enrolled in the examined groups. The study included a group of subjects with PDC who were left untreated during the observation period. These subjects formed the CG, which was used to test the effectiveness of interceptive approaches to PDC.

- None of the examined subjects in either treated groups received any additional orthodontic/surgical therapy beyond cervical pull headgear alone or in combination with RME throughout the observation time; none of the subjects underwent extraction of the deciduous canines either.
- The duration of the observation period for canine eruption (18 months) was appropriate as established by a previous study by Ericson and Kuroi.²⁰
- A superimposition study was performed to assess changes in upper molar position concurrent with alternative interceptive approaches to PDC.

The results of the current study showed that the maintenance or improvement of the perimeter of the upper arch as a measure to intercept palatal displacement of maxillary canines is effective in preventing canine impaction of PDCs (Figure 1A, B). The rate of success in the RME/HG and HG groups (85.7% and 82.3%, respectively) is slightly more favorable than previous results by Olive,²⁴ who found that 75% of the canines emerged after orthodontic treatment with fixed appliances to create space in the upper arch after extraction of the primary canine.

These findings confirmed the outcome of a preliminary report on smaller groups of subjects with PDC by Leonardi and colleagues⁷ and the follow-up study by

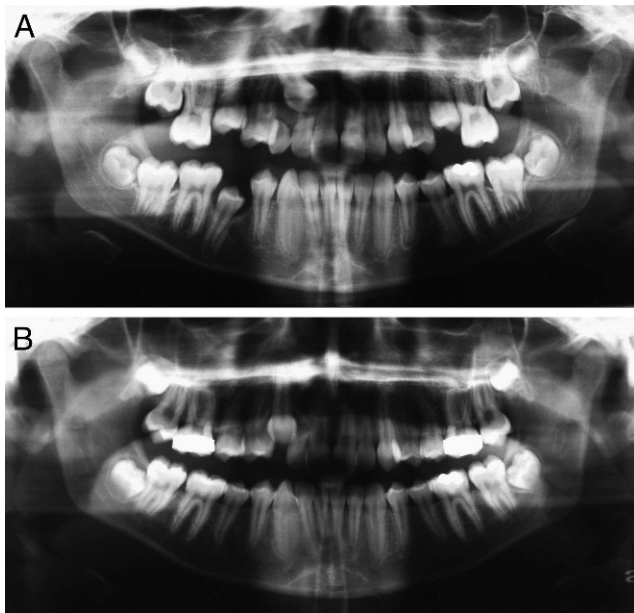


Figure 1. (A) Female patient (enrolled in the headgear group), age 11 years 8 months, with palatally displaced 1.3; (B) After 11 months of headgear treatment (at night only) the canine is fully erupted.

Baccetti and colleagues⁸ in terms of the greater successful eruption of the PDCs with the use of cervical pull headgear. These success rates are higher than those obtained with the extraction of the primary tooth corresponding to the PDC as reported in previous longitudinal studies: 78% according to Ericson and Kuroi²⁰ (who also included PDCs showing just an improvement in the eruption pattern), 62% according to Power and Short,²² and 65.2% according to Baccetti and colleagues.⁸ It should be noted that the permanence of the deciduous canine on the upper arch can be extremely useful in cases requiring surgical/orthodontic approach to impacted PDCs when the evolution of the PDC is unfavorable. The presence of the deciduous canine allows for the tunnel technique, which is one of the procedures indicated for an optimal periodontal success associated with canine repositioning in the long term.³⁰

Interestingly, the superimposition study showed that a significant mesial movement of the upper first molars (about 2.5 mm) occurred in subjects with untreated PDCs. On the contrary, headgear wear resulted in a significant reduction in the amount of mesial displacement of the upper molar that exhibited an actual lack of mesial movement of the molar (0.2 mm). The addition of part-time wear of the cervical pull headgear to the interceptive treatment of PDC apparently restrained the distal segment of the upper dental arch from moving mesially, thus maintaining the space available for canine eruption. It is legitimate to speculate that the goal of avoiding mesial movement of the upper

posterior might be achieved by means of less compliance-dependent appliances than a headgear, such as transpalatal arches or space-holding devices in addition to a palatal Nance button.

With respect to the findings of a very recent study⁹ about the use of RME in the very early developmental phases (at the age of 8 or 9 years) in subjects where PDC had been diagnosed on PA films according to Sambataro and colleagues²⁶ (success rate of about 65%), the present outcomes identified a significantly greater potential of success for the RME approach in combination with a headgear used at a later age (11 years). At this time, the diagnosis of PDC is more reliable⁴ and its interceptive treatment appears to be more successful.

Finally, it should be considered that the orthodontic treatment protocols used in the present study are not specific for the interceptive treatment of PDC. Therefore, the improvement in the eruption rate of PDCs is a significant bonus associated with the expected classical orthodontic outcomes of the two therapies. The use of a headgear combined with RME in subjects with PDCs is therefore indicated in cases presenting with clinical indications for molar distalization or maxillary expansion and molar distalization. In absence of these indications, the favorable outcomes of other interceptive procedures that are specific for the PDC and easier for the patient (such as extraction of the deciduous canine) deserve to be taken into consideration.

CONCLUSIONS

- Orthodontic treatment finalized to the maintenance/improvement of the perimeter in the upper arch in the late mixed dentition (RME and/or cervical pull headgear) can significantly increase the rate of successful eruption of the permanent canine (almost three times more than in untreated controls). These results are achieved without extracting the deciduous canines corresponding to the PDCs.
- In PDC subjects treated with the use of a headgear (alone or combined with RME) the physiological mesial movement of the upper first molars (2.5 mm) is prevented.

REFERENCES

1. Peck S, Peck L, Kataja M. Site-specificity of tooth maxillary agenesis in subjects with canine malpositions. *Angle Orthod.* 1996;66:473–476.
2. Thilander B, Jakobsson S. Local factors in impaction of maxillary canines. *Acta Odont Scand.* 1968;26:145–168.
3. Brin I, Becker A, Shalhav M. Position of the permanent canine in relation to anomalous or missing lateral incisors: a population study. *Eur J Orthod.* 1986;8:12–16.

4. Ericson S, Kurol J. Radiographic examination of ectopically erupting maxillary canines. *Am J Orthod Dentofacial Orthop.* 1987;91:483–492.
5. Baccetti T. A controlled study of associated dental anomalies. *Angle Orthod.* 1998;68:267–274.
6. Chu FC, Li TK, Lui VK, Newsome PR, Chow RL, Cheung LK. Prevalence of impacted teeth and associated pathologies—a radiographic study of the Hong Kong Chinese population. *Hong Kong Med J.* 2003;9:158–163.
7. Leonardi M, Armi P, Franchi L, Baccetti T. Two interceptive approaches to palatally displaced canines: a prospective longitudinal study. *Angle Orthod.* 2004;75:581–586.
8. Baccetti T, Leonardi M, Armi P. A randomized clinical study of two interceptive approaches to palatally displaced canines. *Eur J Orthod.* 2008;30:381–385.
9. Baccetti T, Mucedero M, Leonardi M, Cozza P. Interceptive treatment of palatal impaction of maxillary canines with rapid maxillary expansion: a randomized clinical trial. *Am J Orthod Dentofacial Orthop.* 2009;136:657–661.
10. Rimes RJ, Mitchell CNT, Willmot DR. Maxillary incisor root resorption in relation to the ectopic canine: a review of 26 patients. *Eur J Orthod.* 1997;19:79–84.
11. Ericson S, Kurol J. Resorption of incisors after ectopic eruption of maxillary canines. A CT study. *Angle Orthod.* 2000;70:415–423.
12. Ericson S, Bjerklind K, Falahat B. Does the canine dental follicle cause resorption of permanent incisor roots? A computed tomographic study of erupting maxillary canines. *Angle Orthod.* 2002;72:95–104.
13. Bishara SE. Impacted maxillary canines: a review. *Am J Orthod Dentofacial Orthop.* 1992;101:159–171.
14. McSherry PF. The ectopic maxillary canine: a review. *Br J Orthod.* 1998;25:209–216.
15. Burden DJ, Mullally BH, Robinson SN. Palatally ectopic canines: closed eruption versus open eruption. *Am J Orthod Dentofacial Orthop.* 1999;115:640–644.
16. Usiskin LA. Management of the palatal ectopic and unerupted maxillary canine. *Br J Orthod.* 1991;18:339–346.
17. Mazor Z, Peleg M, Redlich M. Immediate placement of implants in extraction sites of maxillary impacted canines. *J Am Dent Assoc.* 1999;130:1767–1770.
18. Berglund L, Kurol J, Kvint S. Orthodontic pre-treatment for autotransplantation of palatally impacted maxillary canines. Case reports on a new approach. *Eur J Orthod.* 1996;18:449–456.
19. Moss JP. Autogenous transplantation of maxillary canines. *J Oral Surg.* 1968;26:775–783.
20. Ericson S, Kurol J. Early treatment of palatally erupting maxillary canines by extraction of the primary canines. *Eur J Orthod.* 1988;10:283–295.
21. Jacobs SG. Reducing the incidence of unerupted palatally displaced canines by extraction of primary canines. The history and application of this procedure with some case reports. *Aust Dent J.* 1998;43:20–27.
22. Power SM, Short MB. An investigation into the response of palatally displaced canines to the removal of primary canines and an assessment of factors contributing to favourable eruption. *Br J Orthod.* 1993;20:215–223.
23. McConnell TL, Hoffmann DL, Forbes DP, Janzen EK, Weintraub NH. Maxillary canine impaction in patients with transverse maxillary deficiency. *ASDC J Dent Child.* 1996;63:190–195.
24. Olive RJ. Orthodontic treatment of palatally impacted maxillary canines. *Aust Orthod J.* 2002;18:64–70.
25. Buchner HJ. Root resorption caused by ectopic eruption of maxillary cuspid. *Int J Orthod.* 1936;22:1236–1237.
26. Sambataro S, Baccetti T, Franchi L, Antonini F. Early predictive variables for upper canine impaction as derived from posteroanterior cephalograms. *Angle Orthod.* 2005;75:28–34.
27. Becker A, Chaushu S. Dental age in maxillary canine ectopia. *Am J Orthod Dentofacial Orthop.* 2000;117:657–662.
28. Baccetti T, Franchi L, McNamara JA Jr. The cervical vertebral maturation (CVM) method for the assessment of optimal treatment timing in dentofacial orthopedics. *Semin Orthod.* 2005;11:119–129.
29. Björk A, Skieller V. Normal and abnormal growth of the mandible. A synthesis of longitudinal cephalometric implant studies over a period of 25 years. *Eur J Orthod.* 1983;5:1–46.
30. Crescini A, Nieri M, Rotundo R, Baccetti T, Cortellini P, Pini Prato GP. Combined surgical and orthodontic approach to reproduce the physiologic eruption pattern in impacted canine: report of 25 patients. *Int J Period Rest Dent.* 2007;27:529–537.